




ScienceDirect

journal homepage: www.elsevier.com/locate/burns

Irrigation with phosphate-buffered saline causes corneal calcification during treatment of ocular burns

Schrage N.F.^{a,b,*}, Abu Sabah S.^b, Hermanns L.^a, Panfil C.^a, Dutescu R.M.^{a,b}

^a Aachen Centre Of Technology Transfer In Ophthalmology (ACTO e.V.), An-Institute, RWTH Aachen University, ACTO e.V. Karlsburgweg 9, D 52070 Aachen, Germany

^b Department of Ophthalmology, Kliniken der Stadt Köln, D 51109 Cologne, Ostmerheimer Str. 200, Germany

ARTICLE INFO

Article history:

Accepted 23 April 2019

Available online xxx

Keywords:

Corneal calcification

Ocular burn

Phosphate buffer

EVEIT

Decontamination

ABSTRACT

Corneal calcification is a vision-threatening manifestation of calcium containing agents in ocular burn. As we previously reported, our interest was sparked by a particular discrepancy of a case: A patient treated for a non-calcium containing agent in eye burn from exposure to an alkaline mixture of NaOH and KOH, who unexpectedly developed corneal calcification. This current study aims to elucidate whether the 2 min lasting irrigation with a phosphate-buffered saline itself, regardless of rinsing regimen, triggers corneal calcification. The Ex Vivo Eye Irritation Test (EVEIT) system was used on rabbit corneas to replicate the very same phosphate-buffered saline solution the patient was treated with. The rabbit corneas were first burned with 1 M NaOH, rinsed with 4.9% phosphate-buffered saline for 2 min, and were then moisturized with an artificial tear solution for 48 h. All corneas were fluorescein-stained for photo documentation, snap-frozen, lyophilized, and the electrolyte content was analyzed by Energy-Dispersive X-ray spectroscopy (EDX). The EDX analysis revealed pathological phosphorous in corneal stroma after a single rinsing with phosphate-buffered saline. Ongoing application of artificial tears containing physiological 14.581 mmol Ca²⁺ /l led to macroscopically visible calcification, but only in areas of induced corneal erosion. Regardless of the rinsing protocol neither 2 or 15 min of eye rinsing with phosphate containing rinsing solutions, we have given proof that corneal calcification is a foreseeable effect of the phosphate-buffered saline rinsing of mechanically epithelial damaged and chemically burnt eyes. Thus, it is crucial to legally restrict the formulations of phosphate-buffered salines in the medical treatment of eye burns, corneal erosions or chemical splashes of the eye.

© 2019 Elsevier Ltd and ISBI. All rights reserved.

1. Introduction

In the past decade, several reports addressed the controversy of phosphate buffers causing corneal calcification. Questions

arose about whether the application, duration and frequency of phosphate-buffered saline solutions causes corneal calcification and whether a corneal trauma affects corneal calcifications [1–7]. Especially in our publication concerning EVEIT corneas showing calcification after 15 min of rinsing with 0,4%

* Corresponding author at: ACTO e.V. An-Institute, RWTH Aachen University, Karlsburgweg 9, 52070, Aachen, Germany
E-mail address: Schrage@acto.de (N.F. Schrage).

<https://doi.org/10.1016/j.burns.2019.04.022>

0305-4179/© 2019 Elsevier Ltd and ISBI. All rights reserved.

phosphate buffer, in order to re-establish physiological pH on the corneal surface after eye burns, there were doubts whether the more potent 4,9% phosphate buffer, being intended to be applied for only 2 min, results in similar corneal calcification effects as described in Ref. [7]. Thus we performed similar experiments to elucidate the risk of corneal calcifications.

Clinically our attention was attracted by a patient who had unexpectedly developed corneal calcification after a non-calcium containing agent burn from an alkaline mixture of NaOH and KOH [8].

1.1. Case report

A 28 year-old man was at work when he placed a beaker with a highly concentrated mixture of NaOH and KOH on the ground. Some drops of this fluid splashed into his left eye. As a first aid measure at the workplace, there was a special saline solution installed which was formulated with a physiological phosphate buffer containing 4.9% of phosphate buffer (Disodium hydrogen phosphate, $\text{Na}_2\text{HPO}_4 \cdot 12\text{H}_2\text{O}$; Sodium dihydrogen phosphate, $\text{NaH}_2\text{PO}_4 \cdot 2\text{H}_2\text{O}$) in a saline solution of 280 mOsmol/kg. After this immediate first aid treatment, the man was directly transferred to our hospital. The initial examination revealed a white opacification resembling corneal calcification of the inferior cornea in the region of a corneal erosion (Fig. 1). The affected eye was rinsed with amphoteric Diphoterine® (Diphotherine; Sodium chloride; Glycine) following the emergency room protocol of our clinic. Indoor treatment was continued up to corneal epithelium closure.

During therapy we did not use phosphate-containing drugs [13–15]. A one-year follow up examination revealed a persistent calcification without any signs of recovery. Besides enhanced glare sensation in darkness, the patient reported no complaints and had a visual acuity of 20/25.

Consequently, we identified a physiological phosphate-buffered saline solution, applied as first aid for several minutes, as the causative agent. These and other cases resulted in the passing of a 2013 regulation by German authorities (BFARM) recommending physicians to forego the use of phosphate-buffered saline solutions to treat corneal irritation [9]. Even so, salines formulated with highly concentrated phosphate buffers meanwhile have been launched on the market for rinsing chemically burned eyes. The marketing of such formulations, however, contradicts the classifications

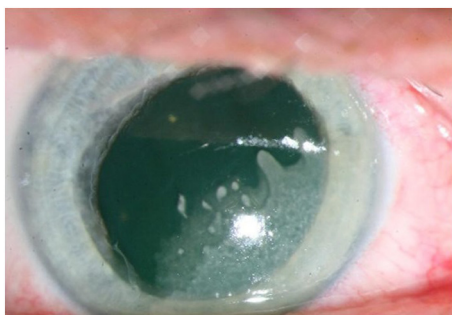

Fig. 1 – Corneal calcification after a non-calciferous burn and rinsing with a phosphate-buffered saline.

of Roper Hall [10] and Reim [11] that maintain that all chemical burns of Class 1 *do show* corneal erosions and phosphate buffers should not be used on irritated eyes as recommended by the BFARM [9]. Nevertheless, critics argue that an initial, single short rinse of no more than 2 min does not risk inducing corneal calcification [1,12]. This notwithstanding, the very low solubility product of $\text{Ca}_3(\text{PO}_4)_2$ of $1.3 \cdot 10^{-32}$ implies that the dissociation equilibrium balance favors the insoluble calcium phosphate and not the ionic state, whereby the precipitation of $\text{Ca}_3(\text{PO}_4)_2$ is imminent. Accordingly, the appearance of calcium phosphate deposits on a phosphate buffer-contaminated cornea ought to lead to immediate corneal calcification (Fig. 3).

To clarify this hypothesis, we present a clinical case with an immediate corneal calcification following a rinsing with a phosphate buffered saline solution. This study aims to address two questions: (1) Whether a single rinsing with a phosphate-buffered saline on an epithelium-free cornea results in a phosphate contamination of the cornea, and 2) Whether further treatment of burnt corneas with ongoing application of artificial tears containing calcium phosphate results in corneal $\text{Ca}_3(\text{PO}_4)_2$ deposits or even visible calcifications. To answer these questions, we set up a condensed set of five different experiments with and without eye burns followed by rinsing with 4.9% concentrated phosphate-buffered saline in concurrence with recommendations for first aid therapy.

2. Materials and methods

2.1. EVEIT system

To simulate a corneal burn or a corneal erosion, we performed Ex Vivo Eye Irritation Tests (EVEIT) on isolated rabbit corneas following the protocol of Frenz [16] and Schrage [7]. Briefly, corneas were derived from slaughterhouse rabbits no more than 3 h after death, excised, placed and cultivated in medium (Minimal Essential Medium Eagle (MEM), HEPES buffer 5.9 g/l)-perfused artificial anterior chambers. After a 24 h precultivation, the corneas were examined to exclude corneal opacification, epithelial or endothelial defects (Fig. 4).

2.2. Corneal toxicity evaluation

All corneas were monitored daily by photographs taken with a high-resolution digital camera (KY-F1030U, JVC, Bad Vilbel, Germany), mounted on a Z16 APO Microscope, Wetzlar, Germany). Fluorescein stains were made with a 0.17% fluorescein saline solution applied for 30 s and by flushing the excess away with 5 ml of fluorescein solution. Then, for illumination, cobalt blue was placed over the corneas, and a photograph was taken. Corneal erosions impose as green stain on the surface. Optical coherence tomography (OCT) of corneas was performed directly after rinsing and on a daily basis, in the case of ongoing artificial tear application (Fig. 5).

2.3. Experimental procedure

2.3.1. Single decontamination after a burn

The first question is: Does treating a corneal burn by rinsing with a 4.9% phosphate-buffered saline (disodium

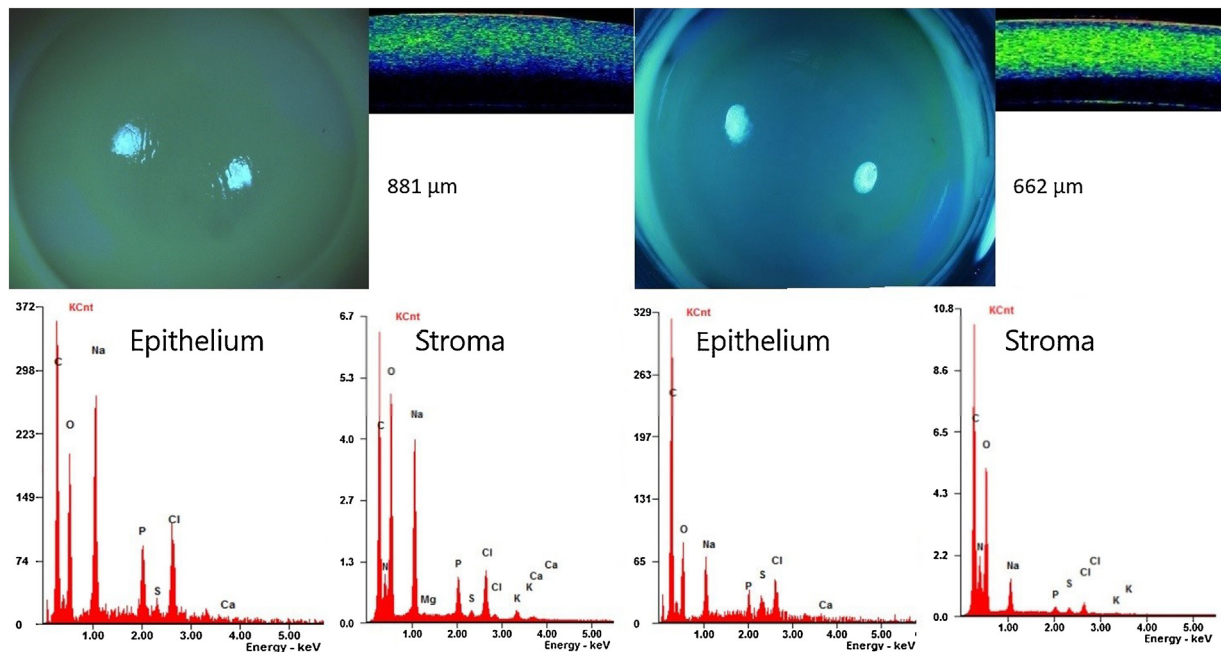


Fig. 2 – Set one, acute burns images represent 2 corneas being burned for 15 s with 1 M NaOH and rinsed for 2 min with 4.9% phosphate-buffered saline. Corneal microstructure and corneal thickness are presented by OCT imaging. Representative EDX analysis results are presented for the corneal epithelium and anterior stroma.

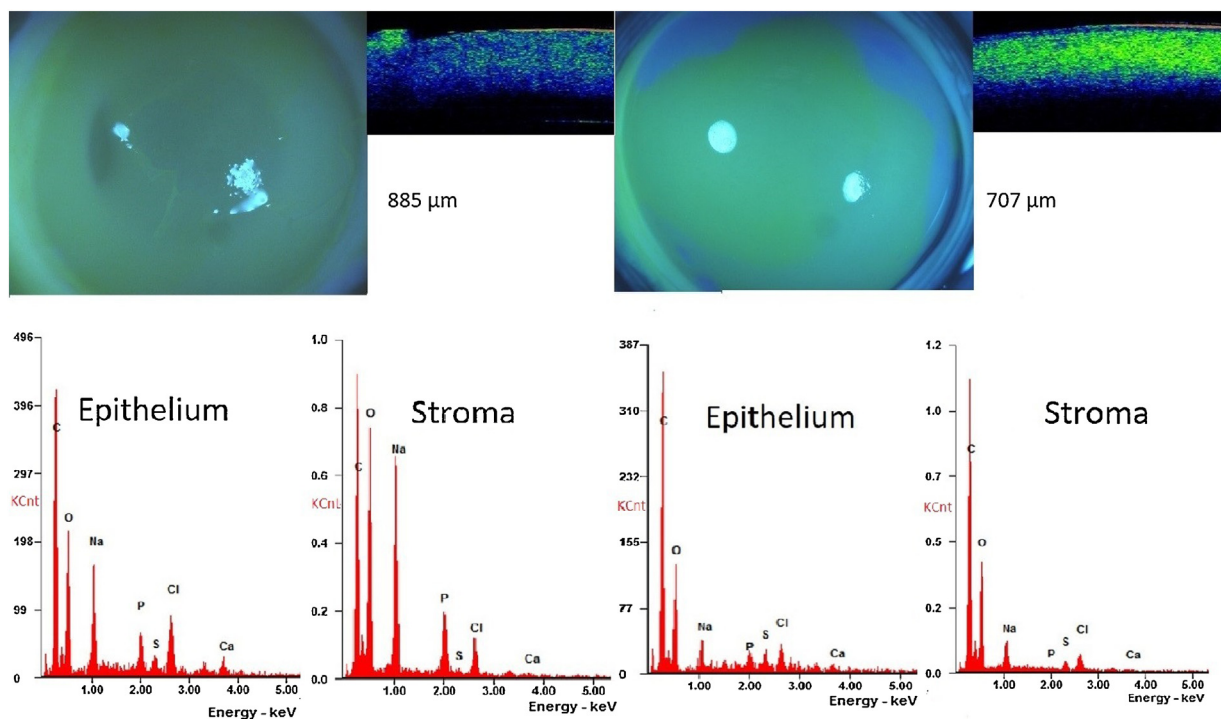


Fig. 3 – Images represent 2 corneas being burned for 30 sec with 1 M NaOH and rinsed for 2 min with 4.9% phosphate-buffered saline. The cornea on the left shows minor corneal calcification. Corneal microstructure and corneal thickness are presented by OCT imaging. Representative EDX analysis results are presented for the corneal epithelium and anterior stroma.

hydrogen phosphate, sodium dihydrogen phosphate) for 2 min induce corneal phosphate deposition sufficient to induce corneal calcification as previously described [2,17]?

2.3.2. Corneal burn and rinsing

To address this question, corneas in the EVEIT system were either burned for 15 s with 1 M NaOH (n=2) or for 30 s with 1 M NaOH (n=2). Therefore, according to the method of

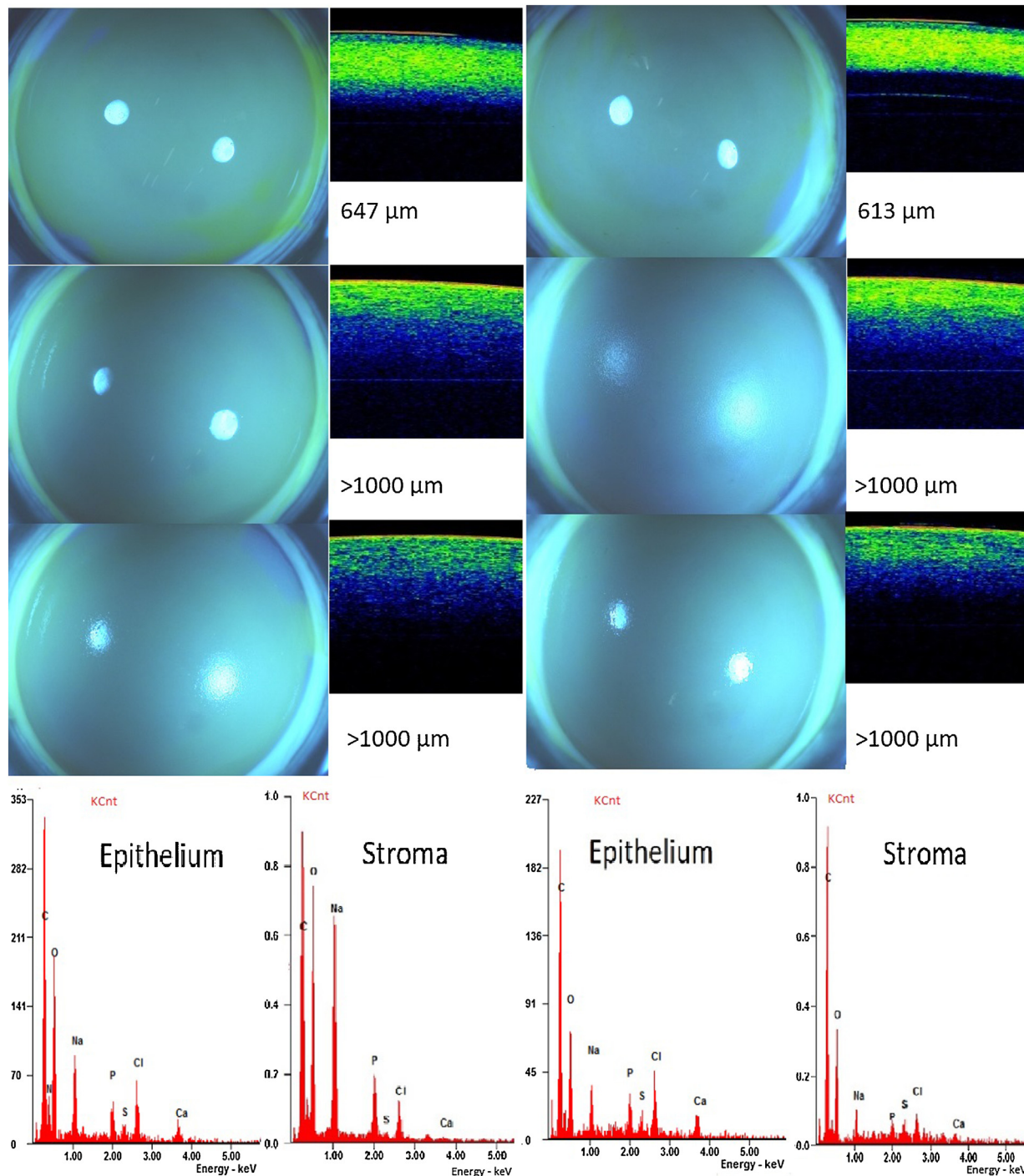


Fig. 4 – Images represent 2 corneas being burned for 15 s with 1M NaOH and rinsed for 2 min with 4.9% phosphate-buffered saline. The first line represents images taken directly after rinsing, the second line after 1 day, and the third line after 2 days of observation under hourly dropping with 14.581 mM CaCl₂ in isotonic saline solution (320 mosm/kg). Corneal microstructure and corneal thickness are presented by OCT imaging. Representative EDX analysis results are presented for the corneal epithelium and anterior stroma.

Schrage et al. [18], a plastic ring with a diameter of 12 mm was placed onto the corneas and was filled with a 1M NaOH solution. After the exposure, the ring was removed, and the corneas were directly rinsed with 4.9% phosphate-buffered saline by super-flushing with a continuous flow with a total volume of 250 ml for 2 min. This period of 2 min was set exactly,

whereby deviations of less than 5 s were considered acceptable. Once the corneas were rinsed, they were immediately removed from the EVEIT chambers and shock-frozen between 2 precooled (−196 °C) aluminum blocks of convex-concave curvature to immediately stop all diffusion processes within corneas for further electrolyte, first of all Ca²⁺ analyses (Fig. 6).

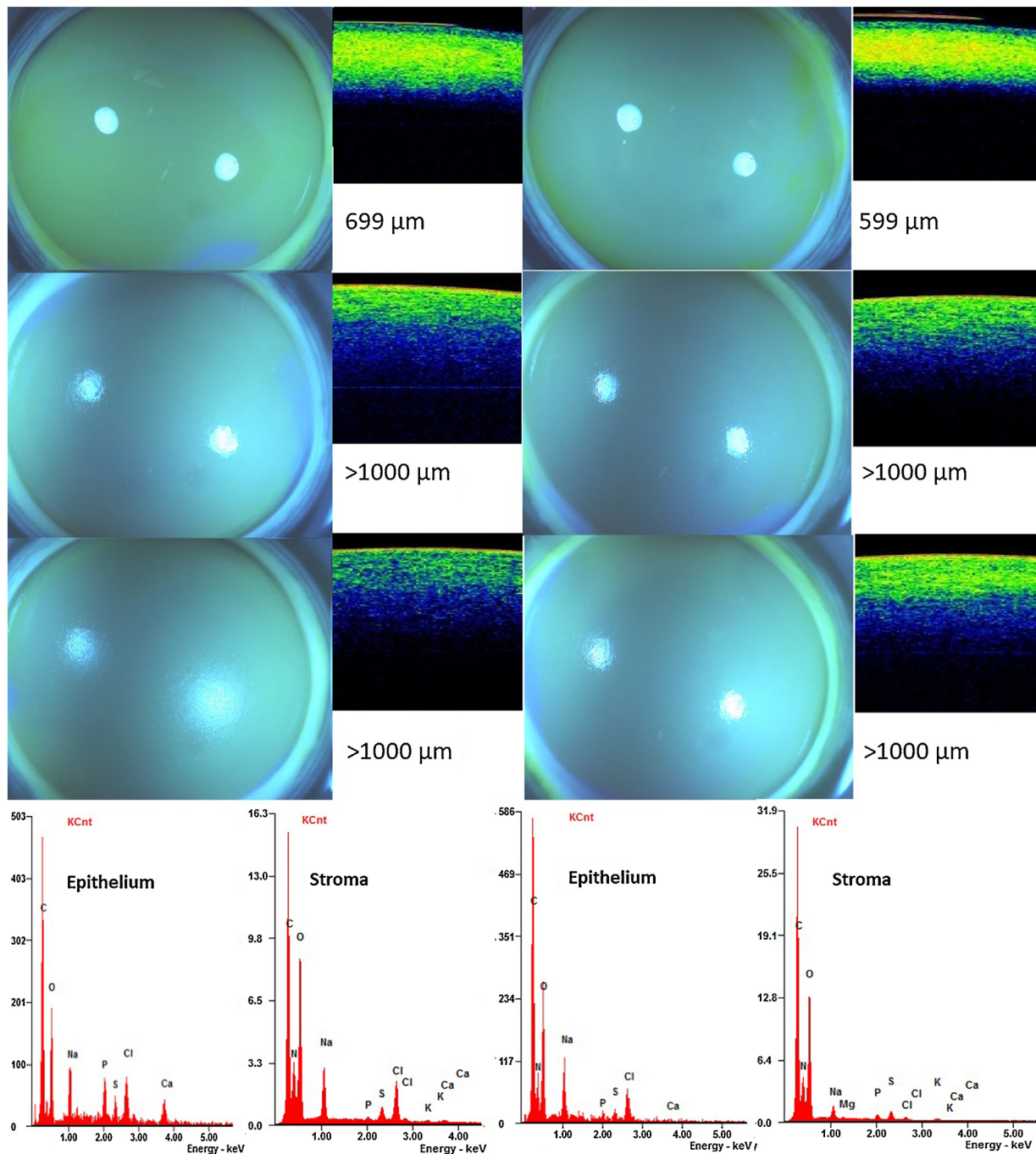


Fig. 5 – Images represent 2 corneas burned for 30 s with 1 M NaOH and rinsed for 2 min with 4.9% phosphate-buffered saline. The first line represents images taken directly after rinsing, the second line after 1 day, and the third line after 2 days of observation under hourly dropping with 14.581 mM CaCl_2 in isotonic saline solution (320 mosm/kg). Corneal microstructure and corneal thickness are presented by OCT imaging. Representative EDX analysis results are presented for the corneal epithelium and anterior stroma. Images resemble a “cooked fish eye” presenting its rough grindy surface and severe corneal edema.

2.3.3. Lyophilization

Corneas to be shock-frozen were dissected into two halves across the apex of the corneas. For corneas with induced corneal erosions, the sections were chosen to cross two of the former mechanical erosion sites. The corneas were then transferred to a lyophilisator in the frozen state and freeze dried under a cooled vacuum. The freeze-drying took place for 24 h so that the corneas were completely dry [19].

2.3.4. EDX-analysis

All samples were mounted on specimen holders for the Scanning Electron Microscope (SEM, SM7000 F, JEOL, Peabody, MA, USA) sputtered with elemental carbon under low pressure vacuum (208 Carbon, Cressington, Watford, UK), X Ray analyzer (Genesis EDAX; Berwyn, PA, USA) [19]. The cutting edges of the corneas were analyzed with fields of $10 \mu\text{m}^2$ size.

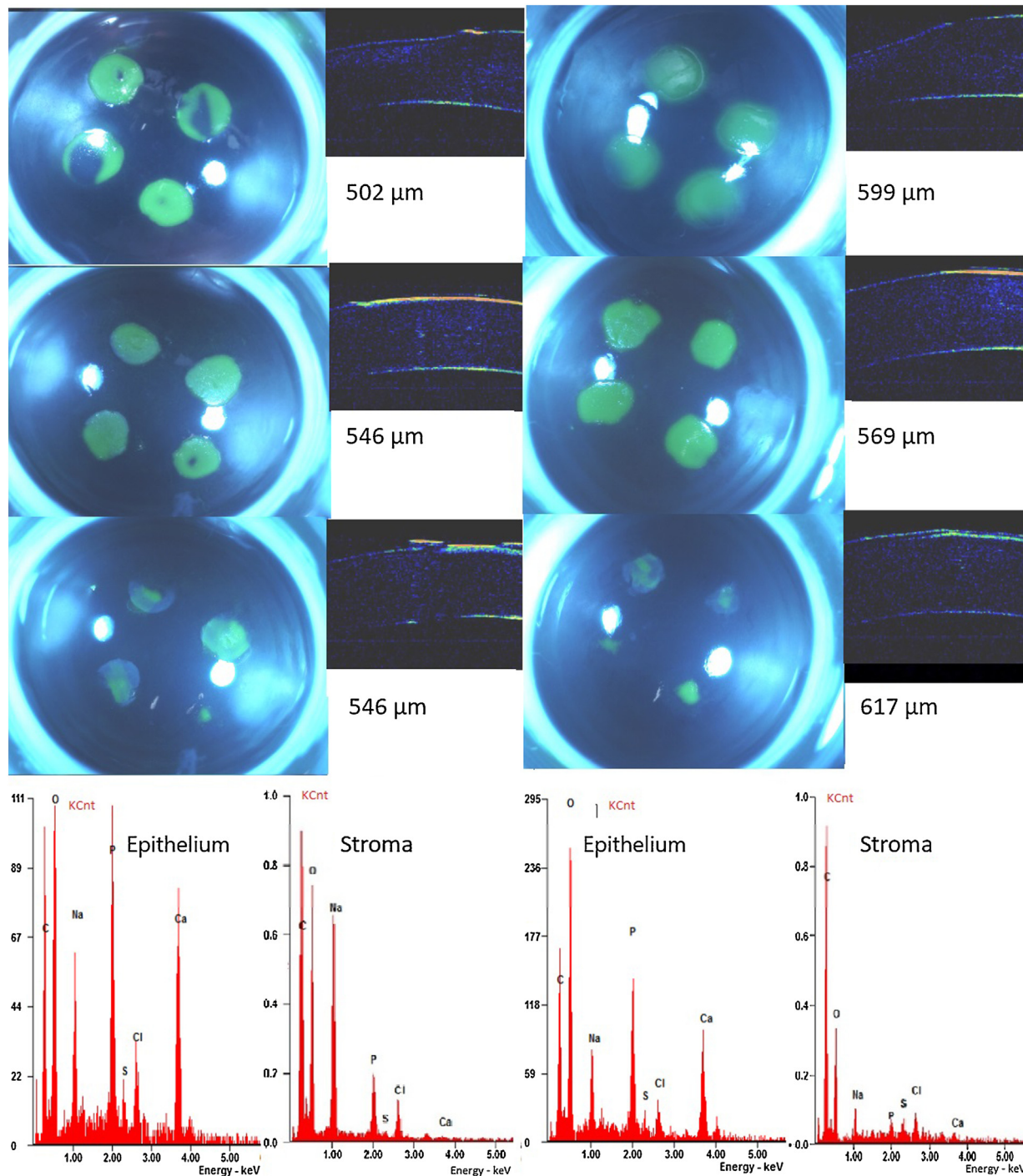


Fig. 6 – Images represent 2 corneas with 4 induced corneal erosions and rinsed for 2 min with 4.9% phosphate-buffered saline. The first line represents images taken directly after rinsing, the second line after 1 day, and the third line after 2 days of observation under hourly dropping with 14.581 mM CaCl_2 in isotonic saline solution (320 mosm/kg). Corneal microstructure and corneal thickness are presented by OCT imaging. Please note the opaque corneal spots in areas of induced erosions after 48 h of observation. These spots were clinically described as corneal calcification and could not be removed by using a cotton swab.

Under an acceleration voltage of 10 KeV, a cumulative acquisition period of 10 s was set, whereby the first lamella of the cornea (epithelium if present) and central stroma were analyzed with 3 measurements for each layer.

2.3.5. *Single rinsing and exposure to free CaCl_2 with or without burn*

The second question is: After eye burns or induced corneal erosion, does corneal calcification occur after a 48 h-treatment

with artificial tears having a physiological calcium ion content?

To address this question, three treatment regimens were added. Here, corneas within the EVEIT were either burned for 15 s with 1 M NaOH ($n = 2$) or for 30 s with 1 M NaOH ($n = 2$). For the third non-burn- group, 4 erosions for each cornea were induced using an abrasive drill. All corneas of each group were rinsed for 2 min in accordance with the aforementioned protocol. Thereafter, corneas were continuously wetted hourly over 48 h with a saline solution containing the exact calcium content of human tears according to data by Lemp et al. [20] but reformulated as CaCl_2 as we described in a previous report [7]. Briefly, the applied artificial tear replacement solution was adjusted to the calcium content of 14.581 mmol Ca^{2+}/l in 0.9% saline solution (Delta Select, Rimbach, Germany). This solution was applied onto the corneas, hourly, providing 11.7 mg of Ca^{2+} . The artificial tears were administered by using a dropping device centered above the apex of corneas, applying 32 μl saline in each drop. A soft-tipped cannula, applying continuous suction, was placed on the limbal rim of cultured corneas to remove excess fluid [7]. Photographs and OCT images were taken daily. Finally, all corneas were shock-frozen as described above.

3. Results

3.1. Corneal morphology

After a single application of a 1 M NaOH solution and rinsing with 4.9% phosphate-buffered saline, corneal edema immediately appeared in all corneas tested. In the case of ongoing observation over 48 h, without induced erosions corneal edema increased to over 1000 μm in all those cases. Fluorescein-stained photographs revealed opaque corneas after ocular burns. For corneas with mechanically induced erosions, a 48 h-application of artificial tear saline led to the appearance of calcified shells in the area of erosions in all cases. These shells were comparable in nature to typical corneal

calcifications seen in human corneas. For corneas without induced erosions, only two corneas showed corneal calcification to some extent.

3.2. EDX results

Elevated levels of phosphorous in the superficial cornea and the anterior stroma were detected after corneas were treated with 4.9% concentrated phosphate-buffered saline. The normal levels of phosphorous are in the order of magnitude of sulfur ions. Even though these electrolytes are severely altered in the case of ocular burns, the appearance of phosphorous in the anterior stroma, even in small amounts, is pathological, as is presented here (Table 1)

In addition, the second set of experiments with continuous tear-like fluid application, revealed elevated levels of phosphorous and calcium within the epithelium, with a regular ion content of the anterior stroma for three out of four corneas. The most severe ionic alterations were detected for corneas with mechanically induced erosions without being burned and observed for 48 h. Here, phosphorous and calcium levels were highly elevated within the epithelium, whereby the anterior stroma showed a high phosphorous content.

4. Discussion

In our previous report on this topic [7], we stated that there is no doubt that mixtures of phosphate and calcium ions immediately form calcium phosphate or calcium apatite. In contrast to this in our publication [7] we did not find any calcification in corneas exposed with corneal epithelial defects to long term dropping of different artificial tears like Hylo LasOP[®] or MEM with an intermediate continued exposure to calcium containing fluid if no phosphate was in the tear substitutes like Hylo-Lasop[®] and MEM thus for our experiments here we did not use this type of drops as controls due to clear evidence that no calcification is the expected and very often proven result of EVEIT exposures without phosphate buffers.

Table 1 – Summary of EDX results.

Corneas	Treatment and burns	Rinsing 4,9% phosphate buffer	Application of Ca^{+} containing eye drops	Epithelial analysis	Stromal analysis
n 1	NaOH 1 mol 15s	+	None	P extremely elevated, Plaque with P/Ca Fig. 1	P present (pathological)
n 2	NaOH 1 mol 15s	+	None	P elevated Fig. 1	P present (pathological)
n 1	NaOH 1 mol 30s	+	None	P elevated Ca present, Plaque with P/Ca Fig. 2	P present (pathological)
n 2	NaOH 1 mol 30s	+	None	P low Fig. 2	P normal
n 1	NaOH 1 mol 15s	+	48h	P/Ca 2:1 high Fig. 4	P present (pathological)
n 2	NaOH 1 mol 15s	+	48h	P/Ca 2:1 high Fig. 4	normal
n 1	NaOH 1 mol 30s	+	48h	P/Ca 2:1 high Fig. 5	normal
n 2	NaOH 1 mol 30s	+	48h	normal Fig. 5	normal
n 1	Mechanical abrasio no burn	+	48h	P/Ca 2:1 extremely high, Plaque with P/Ca Fig. 6	P present (pathological)
n 2	Mechanical abrasio no burn	+	48h	P/Ca 2:1 extremely high, Plaque with P/Ca Fig. 6	P present (pathological)

Evidence of precipitation of calcium phosphate can be given by the knowledge that both compounds have an extreme low water solubility especially low when pH-level increase over 7 and/or temperature rises. For human tears, Stanley [21] Leopold [22] and Caldeira et al. [23] calculated a calcium content to be in the order of 0.0211–0.041 mg/ml with a basic tear secretion rate of 120–240 μ l/h. This results in the introduction of calcium onto the corneal surface from 2.53 to 9.84 mg/h for healthy eyes. As the tear secretion rate is upregulated during an eye injury as simulated here, tear volumes and calcium concentrations above the range mentioned in [21–23] are expected. The producer of the highly concentrated phosphate buffer recommends a two minute duration of eye rinsing with 4.9% phosphate-buffered saline [24]. This is following the instructions sufficient to reach the target of intraocular pH normalization as stated in our previous report [8]. We have argued that corneal calcification under presence of phosphate might occur under certain circumstances in cases of free calcium ions in tears. This current study proves that the circumstance necessary to cause calcifications are both: first eye burns rinsed immediately with 4.9% phosphate-buffered saline, non burnt corneal erosions rinsed for 2 min with 4.9% phosphate buffered saline under the application of physiological saline solution containing physiological calcium levels in our ex-vivo model.

These corneal calcifications are macroscopically visible as whitish opacifications. These calcifications are even more pronounced in the case of unburnt corneas with applied mechanical corneal erosion due to the exposed collagen fibrils underneath the damaged corneal epithelium.

This fact is supported by the clinical case that we cite here. Our study gives insight in the mechanism that corneal calcification does occur after a single corneal contamination with phosphate-buffered saline to treat an ocular burn with corneal erosion. This case was the origin of this current research.

On the molecular level, we described the corneal electrolyte content to be severely altered after immediate rinsing with phosphate-buffered saline after a corneal burn [8]. These data provided insight into post-burned corneas being rinsed for 15 min compared to the here validated protocol of the recommended 2 min rinse with 4.9% phosphate buffer. Therefore, we addressed this uncertainty of the timespan by proving here, that a 2-minute rinsing with a 4.9% phosphate-buffered saline of burned corneas does indeed cause severe alteration of corneal electrolytic content of burnt and non burnt corneas with mechanical erosion compared to that of healthy rabbit corneas. Out of the applied electrolytes by 2 min rinsing and continued calcium-saline application we find these electrolytes in EDX analysis. It is notable that the phosphorous ion level is highly elevated in the anterior and deep corneal stroma initially and in the further dropped corneas, as indicated by EDX analysis. Thus, we are certain that a phosphate contamination of the cornea occurs even from a 2-minute rinsing with 4.9% phosphate-buffered saline. This elucidates the data of [7] where we found a comparable result for a 15 min rinsing with isotonic phosphate buffer. Moreover, in the case of no other treatment, removing this phosphate from the corneal stroma presents a certain risk to induce corneal calcification by the normal phosphate content of tears.

The underlying process of phosphate contamination [25] of the cornea and the so-called “corneal conditioning” [26] takes

place from the first application of an electrolyte solution in the case of a defective corneal epithelial barrier. The argumentation of Daamgard and the Vehyle Hospital [1,12] that a 2-min rinsing with phosphate-buffered saline is harmless is consistent for healthy eyes without corneal erosion, on which they performed their experiments. However, their conclusion that this would be the same for burnt eyes is by these experiments and the clinical case proven as a erroneous and should be rescinded as a dangerous recommendation. Importantly, we give evidence here that a phosphate-contaminated cornea, resulting from a 2-min exposure to a 4.9% phosphate-buffered saline, calcifies with ongoing exposure to a physiological concentration of calcium ions (artificial tears). There is missing evidence that up to now there has been no proof that any phosphate ions being introduced into corneas can be eliminated from the stroma by means of a secondary rinsing with e.g. physiological saline solution.

The cited clinical case provides evidence that exposure to only 0.4% phosphate buffer saline could very well lead to persisting corneal calcification.

Thus, without modifications of the rinsing protocol of 2 min of rinsing, we are convinced that corneal calcification should no longer be dismissed as an ‘unexpected side effect’, but it is a foreseeable effect of the single rinsing of burnt eyes with phosphate-buffered saline. Consequently, the hitherto permissible use of phosphate-buffered saline solutions as the recommended medical treatment of eye burns, corneal erosions or chemical splashes on the eye should be legally banned immediately. The pharmaceutical industry should reformulate its charges of phosphate-buffered saline and the authorities should monitor it. This is in a line with the BFARM recommendation on not using phosphate buffer on corneas with erosions [9].

The more interesting question is now: Why don’t corneal erosions and corneal burns contaminated with phosphate-buffered saline, which is currently a constituent of more of 60% of all eye drops [5,6], result in regular calcifications? Currently, we can explain this fact depending on the particular mechanisms of stabilization of the calcium within the tears and the clearance of phosphate from the corneal stroma in the case of early epithelial closure. Both mechanisms are not yet completely understood. We uncovered first hints for an answer in the work of Langefeld [27] who found micro-calcifications in renal deficiency-related causes of death. This concurs with the newly described research of Jahnen Dechent et al. who describe the protein fetuin to be the main stabilizer of calcium in the blood [28]. This protein is very susceptible for alterations under inflammatory and proteolytic conditions, releasing its calcium with results of calcifications.

5. Conclusions

Altogether, our experiments indicate that any short or long rinsing with phosphate-buffered saline solutions onto eyes with burns and/or corneal erosions should not be performed due to a high risk of later corneal calcification. This risk of corneal calcification, being a highly undesired side effect, is real, in particular, under inflammatory proteolytic conditions like in rheumatic ulcers and eye burns. This has been taken into account by german authorities in the BFARM guideline of

2013. But until now there are medical products in the market with the indication of “corneal burn” and the treatment of “rinsing” containing more or less high concentrations of phosphate buffer. We believe that following the clinical cases published by several groups [1–6], experimental data of [7] and this paper, this indication for phosphate buffers should be withdrawn.

Further experiments should be undertaken to clarify the removal of phosphate after rinsing with phosphate buffered saline from the corneal stroma, to analyze the role of protein in stabilizing calcium and to name those circumstances causing protein destabilization which, in turn, promotes the release of calcium from tissues and tears, inducing corneal calcification.

The EVEIT system, as a model of the anterior ocular segment, has been shown to produce reliable results on corneal toxicity in the case of topical corneal drug application [7,29,30]. Here, we could exemplify the practicability of the EVEIT system for evaluating pharmaceutical products.

Funding

This research did not receive any specific grant from funding agencies in the public, commercial, or not-for-profit sectors.

Conflict of interest

None.

Acknowledgements

The authors would like to thank the *Gemeinschaftslabor für Elektronenmikroskopie*, RWTH Aachen University for their valuable help in revising this manuscript.

REFERENCES

- [1] Brandslund , Damgaard AL. Corneal calcification after chemical eye burns caused by eye drops containing phosphate buffer. *Burns* 2008;34:1215.
- [2] Schrage F, Schlossmacher B, Aschenbrenner W, et al. Phosphate buffer in alkali eye burns as an inducer of experimental corneal calcification. *Burns* 2001;27:459–64.
- [3] Schrage F, Kompa S, Ballmann B, et al. Relationship of eye burns with calcifications of the cornea? *Graefes Arch Clin Exp Ophthalmol* 2005;243:780–4.
- [4] Huige MM, Beekhuis WH, Rijnefeld WJ, et al. Deposits in the superficial corneal stroma after combined topical corticosteroid and beta-blocking medication. *Eur J Ophthalmol* 1991;1:198–9.
- [5] Bernauer , Thiel MA, Kurrer M, et al. Corneal calcification following intensified treatment with sodium hyaluronate artificial tears. *Br J Ophthalmol* 2006;90:285–8.
- [6] Bernauer , Thiel MA, Langenauer UM, et al. Phosphate concentration in artificial tears. *Graefes Arch Clin Exp Ophthalmol* 2006;244:1010–4.
- [7] Schrage F, Frentz M, Reim M. Changing the composition of buffered eye-drops prevents undesired side effects. *Br J Ophthalmol*. 2010;94:1519–22.
- [8] Schrage . Aktuelle Empfehlungen zur optimalen Therapie von Augenverätzungen. *Zeitschrift für praktische Augenheilkunde Augenärztliche Fortbildung* 2010;3:327–32.
- [9] Blumberg A. Phosphatpuffer in Ophthalmika- Risiko für Hornhautkalkifizierungen. *BFARM: Bulletin zur Arzneimittelsicherheit* 2013, 1. Paul Ehrlich Institut; 2013. p. 7–12.
- [10] Roper-Hall J. Thermal and chemical burns. *Trans Ophthalmol Soc U K* 1965;85:631–53.
- [11] Reim . Ein neues Behandlungskonzept für schwere Verätzungen und Verbrennungen der Augen. *Klin Monbl Augenheilkd*. 1990;196:1–5.
- [12] Damgaard L, Hovendal MP, Schröder HD, Saxtorph H, Bollen P. First aid treatment of alkali eye burns with phosphate buffer does not cause corneal calcifications. Poster, *EAPCCT XXIX International Congress in Stockholm*. .
- [13] Bernauer , Thiel MA, Rentsch KM. Phosphate concentration in ophthalmic corticoid preparations. *Graefes Arch Clin Exp Ophthalmol* 2008;246:975–8.
- [14] Bernauer , Thiel MA, Rentsch KM. Phosphate concentrations in antiglaucoma medication. *Klin Monbl Augenheilkd* 2007;224:249–51.
- [15] Bernauer , Thiel MA, Rentsch KM. Phosphat in Augenheilkundlichen Lösung. *Ophthalmologe* 2006;103:416–7.
- [16] Frentz , Goss M, Reim M, et al. Repeated exposure to benzalkonium chloride in the Ex Vivo Eye Irritation Test (EVEIT): observation of isolated corneal damage and healing. *ATLA* 2008;36:25–32.
- [17] Kompa , Schareck B, Tympner J, Wüstemeyer H, Schrage NF. Comparison of emergency eye-wash products in burned porcine eyes. *Graefes Arch Clin Exp Ophthalmol* 2002;240:308–13.
- [18] Schrage F, Schlossmacher B, Aschenbrenner W, Langefeld S. Phosphate buffer in alkali eye burns as an inducer of experimental corneal calcification. *Burns* 2001;27:459–64.
- [19] Schrage F, Benz K, Beaujean P, et al. A simple empirical calibration of energy dispersive X-ray analysis (EDXA) on the cornea. *Scanning Microsc* 1993;7:881–8.
- [20] Lemp A, Ralph RA. Rapid development of band keratopathy in dry eyes. *Am J Ophthalmol* 1977;83:657–9.
- [21] Stanley A. Water permeability of the human cornea. *Arch Ophthalmol* 1992;87:568–73.
- [22] Leopold H, Lieberman TW. Chemical injuries of the cornea. *Fed Proc* 1971;30:92–5.
- [23] Caldeira A, Sabbaga E, Ianhez LE. Conjunctival and corneal changes in renal failure. Influence of renal transplantation. *Br J Ophthalmol* 1970;54:399–404.
- [24] Online 14.08.2016: <http://www.plum-deutschland.de/produkte/erste-hilfe/augenspuelung/ph-neutral>.
- [25] Schrage F, Kompa S, Haller W, et al. Use of an amphoteric lavage solution for emergency treatment of eye burns. First animal type experimental clinical considerations. *Burns* 2002;28:782–6.
- [26] von Fischern , Lorenz U, Burchard WG, et al. Changes in mineral composition of rabbit corneas after alkali burn. *Graefes Arch Clin Exp Ophthalmol* 1998;236:553–8.
- [27] Langefeld , Reim M, Redbrake C, Schrage NF. The corneal stroma: an inhomogeneous structure. *Graefes Arch Clin Exp Ophthalmol* 1997;235:480–5.
- [28] Keyzer A, de Borst MH, van den Berg E, et al. Calcification propensity and survival among renal transplant recipients. *J Am Soc Nephrol* 2016;27:239–48.
- [29] Pinheiro , Panfil C, Schrage N, et al. The impact of glaucoma medications on corneal wound healing. *J Glaucoma* 2016;25:122–7.
- [30] Dutescu M, Panfil C, Merkel OM, et al. Semifluorinated alkanes as a liquid drug carrier system for topical ocular drug delivery. *Eur J Pharm Biopharm* 2014;88:123–8.